


PRESENTING CLINICAL SIGNS

History: Grade 2/6 murmur. Had a single episode of increased respiratory rate/panting at rest that resolved on its own.

DATE

4/25/23

ECHOCARDIOGRAPHIC FINDINGS

2D, M-mode, and Doppler study.

PERFORMED BY:

Kelly Vazquez

Left atrial size is normal. The mitral valve leaflets are mildly thickened, and a mild jet of eccentric mitral regurgitation is present. Left ventricular dimensions are normal, as is left ventricular systolic function. The aorta and aortic valve are normal. Right atrial and right ventricular dimensions are normal. The tricuspid valve is normal. The pulmonary artery and pulmonic valve are normal. No shunting lesions are visualized. No pericardial effusion or cardiac masses are seen.

INTERPRETED BY

 Keith Blass, DVM,
 MS, DACVIM
 (Cardiology)

 LA - 33.9 mm
 LVIDd - 33.6 mm
 LVIDs - 22.3 mm
 FS - 33.6%
 RA - 23.3 mm
 LVOT - 1.35 m/s
 RVOT - 0.77 m/s

PATIENT

Gigi Vastano

ASSESSMENT/RECOMMENDATIONS

Degenerative mitral valve disease

SPECIES

Canine

This examination demonstrates mild regurgitation of blood across Gigi's mitral valve resulting from degenerative valve disease. The hemodynamic effects of the regurgitation also appear to be mild, as Gigi does not have secondary dilation of either her left atrium or left ventricle, and her left ventricular systolic function is normal. As such, Gigi's mitral valve disease appears to be well-compensated, and is unlikely to be the cause of her episode of panting at rest.

BREED

Catahoula Mix

No therapy is recommended at this stage of disease.

A recheck echocardiogram is recommended in 6 months to monitor for disease progression.

SEX

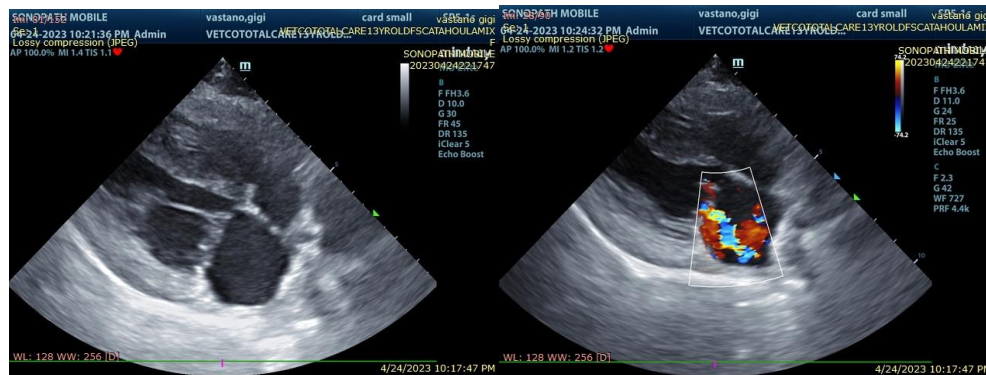
FS

AGE

13 y

WEIGHT

38 lb


HOSPITAL NAME

Vetco Total Care

The information and recommendations provided are based on the images presented by the referring veterinarian. No evaluation can be communicated regarding pathology that was not visible in the image/video clips provided.

REFERRING VET

Dr. Mohammed

Thank you for this referral. If the clinical or image interpretation does not parallel your findings or



if I can be of any further assistance please contact me.

DATE

4/25/23

Keith Blass, DVM, MS, DACVIM (Cardiology)

KeithBlass@gmail.com

631-804-5754

PERFORMED BY:

Kelly Vazquez

INTERPRETED BY

Keith Blass, DVM,

MS, DACVIM

(Cardiology)

PATIENT

Gigi Vastano

SPECIES

Canine

BREED

Catahoula Mix

SEX

FS

AGE

13 y

WEIGHT

38 lb

HOSPITAL NAME

Vetco Total Care

REFERRING VET

Dr. Mohammed